



Predicting final results of brace treatment of adolescents with idiopathic scoliosis: first out-of-brace radiograph is better than in-brace radiograph—SOSORT 2020 award winner

Negrini Stefano^{1,2} · Francesca Di Felice³ · Negrini Francesco² · Rebagliati Giulia³ · Zaina Fabio³ · Donzelli Sabrina³ 

Received: 3 November 2020 / Revised: 1 February 2022 / Accepted: 28 February 2022
© The Author(s) 2022

Abstract

Purpose In-brace radiograph of adolescents with idiopathic scoliosis (AIS) has been shown to reflect brace efficacy and the possibility of achieving curve correction. Conversely, the first out-of-brace radiograph could demonstrate the patient's ability to maintain the correction. We aimed to determine which of the two radiographs is the best predictor of the Cobb angle at the end of treatment (final radiograph).

Design Retrospective cohort study of a prospective dataset.

Methods The population was selected based on the following inclusion criteria: AIS, age 10–18 years; Risser score 0–2; Cobb angle 25–40°; brace treatment; availability of all radiographs. Statistics: Pearson correlations provide a first exploration of data. The univariate and multivariate logistic regression model tested the predictors. Finally ROC curve provided a check of model accuracy.

Results A total of 131 patients were included (mean age 13.0 ± 1.3 , Cobb angle $33.2 \pm 5.5^\circ$; 78% females). At the end of treatment, 56% had stabilised, 9% had progressed, and 44% had improved. The difference between the in-brace and final radiographs was $8.0 \pm 6.0^\circ$, while the difference between the first out-of-brace and final radiographs was $1.8 \pm 5.2^\circ$. The best predictor of final outcome was the first out-of-brace radiograph (0.80), compared to in-brace (0.68) and baseline (0.59) radiographs. The best cut-offs to predict avoidance of progression were 30% and 10% of the correction rates for the in-brace and first out-of-brace radiographs, respectively.

Conclusion The first out-of-brace radiograph predicts end results better than the in-brace radiograph. It offers an excellent clinical reference for clinicians and patients. The first out-of-brace radiograph should be considered an essential element of future predictive models.

Level of Evidence 1 Diagnostic: individual cross-sectional studies with consistently applied reference standard and blinding.

Keywords Scoliosis · Brace · Radiograph · COBB angle

Introduction

Scoliosis is a three-dimensional deformity with maximal progression during growth [1]. When the risk of progression is high, the Risser score is between 0 and 2. When scoliosis

is between 25 and 40 degrees, brace treatment is required [1]. Randomised controlled trials (RCTs) have confirmed bracing effectiveness [2, 3], supporting the conclusions of a large number of observational studies [4–6]. Brace effects depend on different factors: the deformity's characteristics, brace type, construction and material used, brace wear dosage, patients' reactions to the brace, and correct and consistent brace wear throughout therapy [7, 8].

In-brace radiograph (IB-XR) has traditionally been considered a proxy for brace quality. It has been used to determine the effect of bracing, predict the end-of-growth results, and compare the impact of different braces [9]. Katz recommended a 25% in-brace correction rate since it was associated with a 73% success rate [10]. Other

✉ Donzelli Sabrina
sabrina.donzelli@isico.it

¹ Department of Biomedica, Surgical and Dental Sciences, University “La Statale”, Milan, Italy

² IRCCS Istituto Ortopedico Galeazzi, Milan, Italy

³ Istituto Scientifico Italiano Colonna Vertebrale (ISICO), Milan, Italy

authors have suggested a 40–50% correction rate to halt progression [4, 11, 12]. The SOSORT consensus on brace action agreed that the initial in-brace correction or primary correction, together with compliance, are the most important factors in predicting treatment success [13]. The factors determining in-brace correction include the Cobb angle of all curves, the lumbopelvic relationship, and the sagittal and coronal imbalance [4, 14]. Nevertheless, the correction rate does not always reflect the brace effectiveness [15]. The in-brace correction varies according to the orthotic device, such as hypercorrective, Cervico-Thoraco-Lumbo-Sacral Orthosis (CTLSO), and Thoraco-Lumbo-Sacral Orthosis (TLSO). Individual subject characteristics influence this outcome, such as spine flexibility, vertebral rotation, skeletal maturity [16], curve magnitude, curve type, and localisation [7].

According to our clinical experience, we hypothesised that the IB-XR reflects the spine's potential for correction, while the first out-of-brace radiograph (FOB-XR) taken at the end of daily weaning from the brace shows the ability of the patient to maintain the correction, which is linked to his/her muscle strength and neuromotor capacity [17].

Consequently, the end-of-treatment radiograph (EOT-XR) is expected to be different from the IB-XR, while the FOB-XR could act as a target to be achieved during gradual weaning off the brace and for the end-of-growth result. This study aimed to determine if FOB-XR is better than IB-XR at predicting the outcome in a cohort of consecutive patients treated with a brace for adolescent idiopathic scoliosis (AIS) until the end of growth.

Methods

Study design

This was a retrospective observational cohort study, analysing prospective routinely collected data.

Participants

On the search date (18-1-2019), the original sample included 14,507 patients affected by spinal deformities, with an age range of 10–18 years. We applied SRS standard criteria for inclusion [18]: Risser score 0–2; Cobb angle 25–40°; age over 10 years. Furthermore, we included only patients with the availability of baseline radiograph within 3 months from the first evaluation; IB-XR within 1 month and FOB-XR within 6 months from brace start; and end of treatment radiograph after 48 h without the brace. Exclusion criteria were the diagnosis of secondary scoliosis or other associated neurological disorders, treatment discontinuation, and not finishing treatment.

Protocols

At the start, all patients had a baseline radiograph taken within 3 months of the first visit. Figure 1 shows the radiographic protocol. The Italian National Health system takes an average of 2 months to provide braces for free to scoliosis patients. The IB-XR is taken after 1 month of regular brace wear. The time between the START-XR and IB-XR ranges from 4 to 6 months. The FOB-XR is taken after 4–6 months of brace wear, i.e. 7–9 months

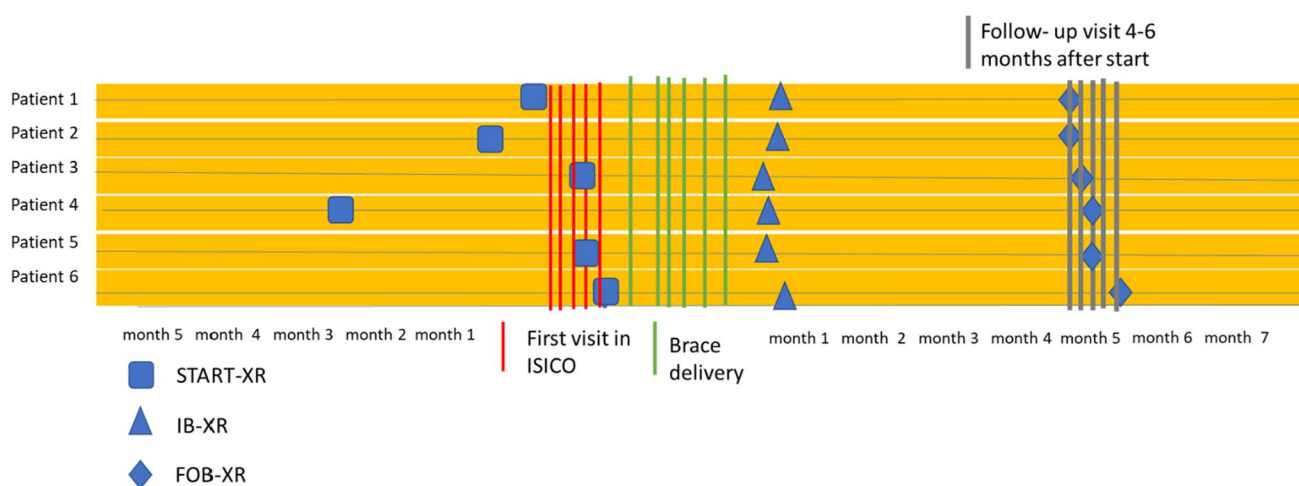


Fig. 1 The radiographic protocol. Each horizontal path represents a different patient's timeline. The red vertical lines represent the first consultation, the green and grey lines represent brace delivery and

the second consultation. START-XR: baseline radiograph. IB-XR: in-brace radiograph; FOB-XR: first out-of-brace radiograph

after the START-XR. We always prescribe brace wearing for a minimum of 18 h to a maximum of 24 h per day. The FOB-XR is always taken at the end of the prescribed daily wearing period. This interval varies from a minimum of 0 h to a maximum of 6 h without the brace. The end-of-treatment radiograph (END-XR) is taken at the end of growth, after 48 h without the brace. Figure 2 shows an example of radiographs taken during the treatment of one patient. Previous studies have described the braces we used [19]. Brace treatment always includes scoliosis-specific exercises [19]: in almost 50% of cases, these follow the Scoliosis Scientific Exercises Approach (SEAS) school [20], while the remaining can be described as usual physiotherapy [21].

Model variables

We measured the Cobb angle on the following radiographs:

- START-XR: first radiograph within 3 months of the baseline clinical evaluation
- IB-XR: 1 month after starting brace treatment
- FOB-XR: after 4–6 months of brace wear
- EOT-XR: last radiograph to decide if treatment should be stopped; this radiograph is taken after 48 h without the brace

Primary outcome variables

The primary outcome variable was defined by multiple binary outcome variables, obtained by measuring the result at the EOT-XR according to recognised clinically crucial thresholds [22]. The 30° Cobb threshold represents the “safety” threshold, which implies no problems in adulthood. The 45° Cobb threshold, close to the surgical threshold, is associated with higher risks of progression in adulthood [1]. We considered a variation within 5° Cobb from START-XR to EOT-XR to define curve changes according to the measurement error of the Cobb method [23].

Secondary outcome variable

The secondary outcome was defined by a continuous variable represented by the change in Cobb angle from START-XR to EOT-XR.

Explanatory variables

The primary explanatory variable was the Cobb angle at the most significant curve, measured on all radiographs taken from baseline to the end of treatment. Furthermore, to account for baseline characteristics, we tested the following variable in both univariate and multivariate models: Cobb angle, TRACE score for trunk aesthetic, rib hump in millimetres, angle of trunk rotation in degrees (ATR) and

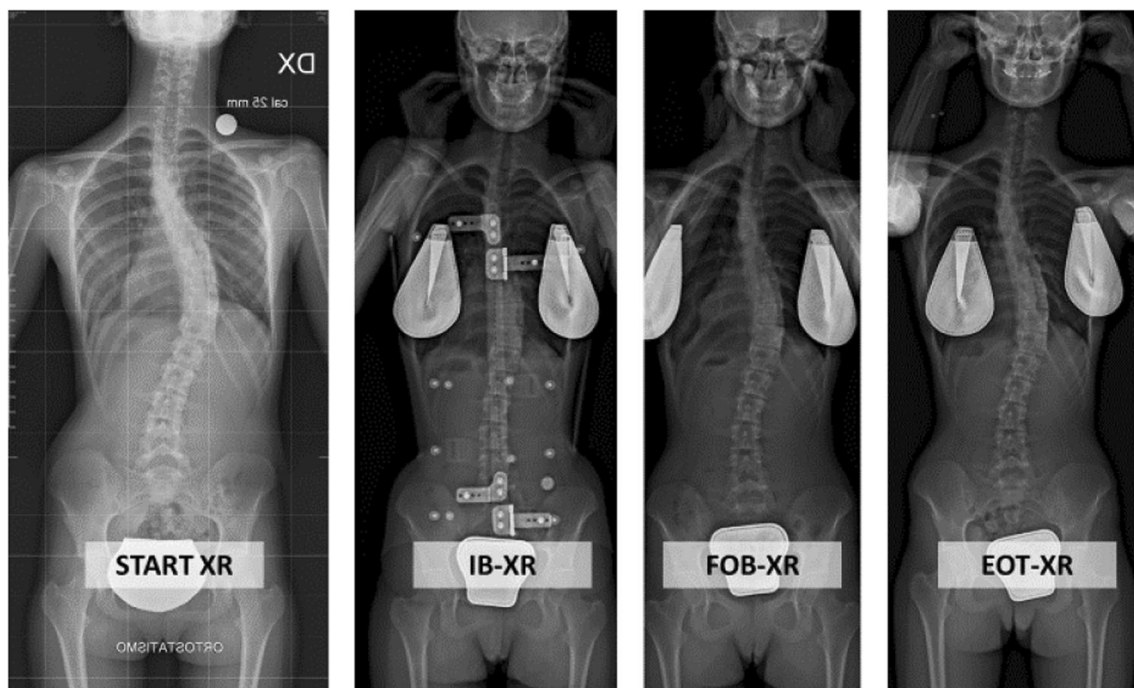


Fig. 2 Example of radiographic protocol of one patient with a right thoracic curve starting at 54° and improving to 28° in-brace, 33° in the first out-of-brace radiograph and 36° at the end of treatment

Risser score. If a variable showed no significant effect in the univariate model, the variable was not included in the multivariate model.

Statistics

All analyses were conducted with STATA version 15.0 for Windows. We used descriptive and inferential statistics for demographic descriptions according to the data distribution. A preliminary investigation of the association between radiograph measurements and the end-of-treatment Cobb angle was done through the Pearson correlation. To test the role of different radiographs in predicting the outcomes at the end of treatment, we performed sequential univariate and multivariate binary logistic regression models for binary response variables. During model specification, the choice of explanatory variables included in the final multivariate model was guided by the performance of the variables in the univariate model. During model calibration, we tested the accuracy of the provided models by drawing the Receiver Operator Curve (ROC) for the different cut-offs of the rate of correction of IB-XR and FOB-XR and for Cobb changes from START-XR to EOT-XR.

For the secondary analysis, we ran a univariate linear regression model. We ran stepwise forward and backward regression to select the variables included in the final multivariate model.

Results

Patient characteristics

We included 131 subjects. Seventy-eight per cent were female, with a mean age of 13.0 ± 1.3 years and an average Cobb angle at the most significant curve of $33.2 \pm 5.5^\circ$ (Table 1).

Fifty-six per cent of the participants showed stabilisation of their largest curve at the end of the treatment (i.e. progressed less than 5 Cobb degrees), 9% had progressed, and 44% had a reduction of 6 Cobb degrees or more from the baseline (i.e. improved). The Cobb variation between IB-XR and EOT-XR was $8.0 \pm 6.0^\circ$, and the Cobb variation between FOB-XR and EOT-XR was $1.8 \pm 5.2^\circ$.

The highest correlation found was 0.80 between the FOB-XR and EOT-XR (Table 2).

The univariate model showed that the odds ratio (OR) of ending below 30° increased by 21% as the Cobb angle at baseline decreased (OR = 0.79, CI 95% 0.73–0.86, $p=0.000$); 20% as the IB-XR Cobb decreased (OR = 0.80, CI 95% 0.74–0.87, $p=0.000$) and 31% as the FOB-XR Cobb decreased (OR = 0.69, CI 95% 0.61–0.78, $p=0.000$). The size of the hump in millimetres (OR 0.94, CI 95% 0.89–1.00) and the TRACE score (OR 0.98, CI 95% 0.95–1.00) were added to the final multivariate logistic model, but they had no influence on the OR of the IB-XR nor the FOB-XR. The

Table 1 Demographic description of the sample. SD Standard Deviation. The – sign indicates a reduction in curve magnitude, while the + sign indicates a progression. The 5 Cobb degrees threshold is considered clinically significant. The – sign indicates a reduction in the curves, while a + sign indicates an increase in the Cobb angle. The alpha level significance was set at $p < 0.05$. Confidence Interval at 95% (CI 95%)

	Number	Mean (SD)	Minimum	Maximum
Age (years)	131	13.0 (1.4)	10	16
Baseline Cobb angle	131	33.2 (5.5)	25	40
In-brace Cobb angle	131	20.9 (7.3)	7	38
First out-of-brace Cobb angle	131	27.1 (11.1)	9	61
End-of-treatment Cobb angle	131	28.9 (7.9)	8	50
In-brace correction (%)	131	37.4 (17.6)	–27%	77.4%
Out-of-brace correction (%)	131	18.5 (17.0)	–52.5%	64%
Change in Cobb angle from in-brace to end-of-treatment radiograph	131	–8.0 (6.0)	–5	29
Change in Cobb angle from out-of-brace to end-of-treatment radiograph	131	+1.8 (5.2)	–12	20

Table 2 Results of the Pearson correlation. The first out-of-brace radiograph correlated with final outcome better than in-brace and baseline radiographs

Pearson correlation	Baseline radiograph	In-brace radiograph	First out-of-brace radiograph	End-of-treatment radiograph
Baseline radiograph	1.00			
In-brace radiograph	0.55	1.00		
First out-of-brace radiograph	0.63	0.69	1.00	
End-of-treatment radiograph	0.59	0.68	0.80	1.00

predictor variables included in the unadjusted and adjusted binary logistic regression model were not significantly associated with the failure outcome. The odds of stability or improvement were 28% higher for 1° Cobb variation from baseline to IB-XR (CI 95% 1.1–1.6) and 28% higher for each degree of Cobb variation from START-XR to FOB-XR (CI 95% 1.1–1.5) (Table 3).

Furthermore, when considering the correction rate, the odds of ending the treatment without progression was 5% higher per unit per cent increase in the rate of correction obtained at IB-XR and 10% higher per unit per cent increase in the rate of correction obtained at the FOB-XR (CI 95% 1.07–1.12) (Table 4).

We did not develop the multivariate model because none of the clinical baseline characteristics significantly predicted the odds of ending without progression. Considering the widespread use of the rate of correction as a reference for

treatment performance, we decided to test the accuracy of this binary model. ROC curves were drawn for the different cut-offs of the correction rate for IB-XR and FOB-XR and for changes from START-XR to FOB-XR. The IB-XR correction rate compared to the FOB-XR correction rate for the main cut-off point is shown in Table 5. The best cut-off to predict the avoidance of progression was 30% of the correction rate. The best cut-off of the FOB-XR was 10% of the correction rate.

The ROC showed an acceptable balance between specificity and sensitivity of the model, with an AUC of 72% and 78% for IB-XR and FOB-XR, respectively (Fig. 3).

End-of-treatment Cobb angle is predicted by the following regression equation (R squared 0.88): Cobb at end = 1.81 (intercept) + 0.57 (Cobb at FOB-XR) + 0.30 (IB-XR) + 0.17 (Cobb at baseline), as shown by the adjusted coefficients reported in Table 6.

Table 3 Cobb variation and unadjusted odds ratio (OR) for progressing less than 5 Cobb degrees (i.e. avoiding progression outcome). The alpha level significance was set at $p < 0.05$. CI 95%: confidence interval at 95% SE: standard error

Avoiding progression (changes within the 5 Cobb degrees measurement error)	Unadjusted OR	SE	P value	CI 95%	Pseudo R2
Cobb change from START-XR to IB-XR	1.28	0.12	0.005	1.1–1.6	0.21
Cobb change from IB-XR to FOB-XR	0.94	0.05	0.25	0.84–1.05	0.02
Cobb change from START-XR to FOB-XR	1.28	0.06	0.005	1.1–1.5	0.21

Table 4 Rate of correction and univariate odds ratio (OR) for progression of less than 5 Cobb degrees (i.e. avoiding progression outcome). The alpha level significance was set at $p < 0.05$. CI 95%: confidence interval at 95%; SE: standard error

Avoiding progression	Unadjusted OR	SE	P value	CI 95%	Pseudo R2
IB-XR correction rate	1.05	0.02	0.01	1.01–1.10	0.11
FOB-XR correction rate	1.10	0.03	0.003	1.03–1.14	0.21

Table 5 Accuracy of the prediction of avoidance of progression of the in-brace (IB-XR) correction rate compared to the first out-of-brace (FOB-XR) correction rate. OR: odds ratio +LR: positive likelihood Ratio – LR: negative likelihood ratio

Avoid progression OR predicted by IB-XR rate of correction cut-off	Sensitivity (%)	Specificity (%)	Correctly classified (%)	LR +	LR –
<i>In-brace radiograph correction rate</i>					
20% correction	89	44	86	1.60	0.24
30% correction	71	67	71	2.13	0.43
40% correction	44	78	47	1.99	0.72
50% correction	29	89	33	2.58	0.80
<i>Avoid progression OR predicted by first out-of-brace rate of correction rate</i>					
10% correction	79	67	78	2.36	0.32
20% correction	44	89	47	3.98	0.63
30% correction	21	89	26	1.92	0.89
40% correction	13	89	18	1.18	0.98

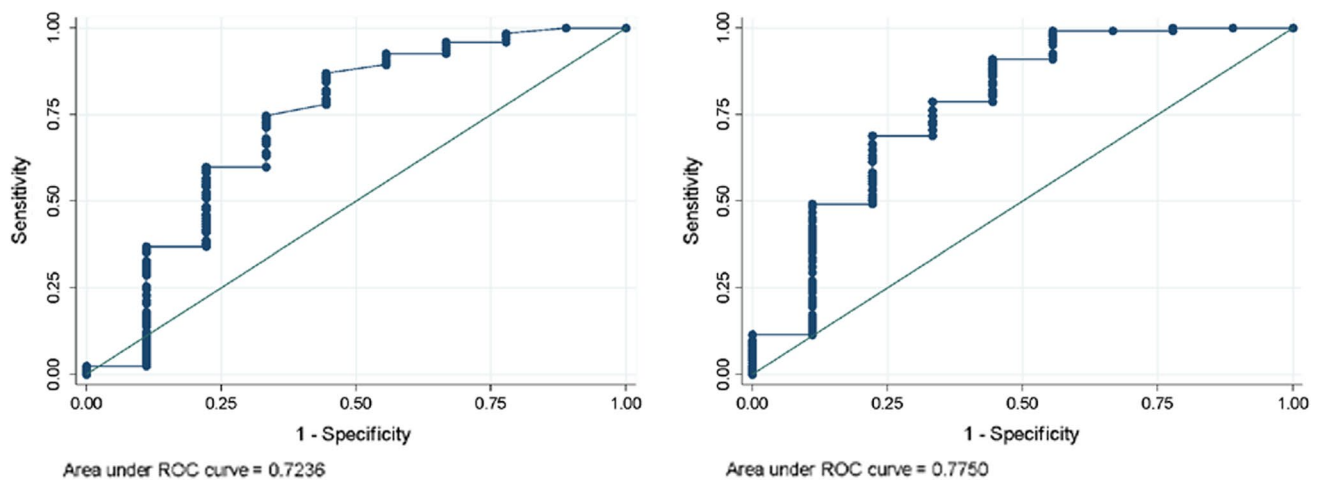


Fig. 3 Receiver operator curve (ROC) and area under the curve (AUC) of the accuracy of the prediction of avoidance of progression of the in-brace (IB-XR) correction rate, on the left side, compared to the first out-of-brace (FO-XR) correction rate

Table 6 Results of the linear regression model crude and adjusted coefficients are reported, alpha level significance was set at $p < 0.05$, CI 95% confidence interval at 95%

End Cobb angle	Crude coefficient	<i>P</i> value	CI 95%	Adjusted coefficient	<i>P</i> value	CI 95%
Start Cobb angle	0.85	0.000	0.64–1.05	0.17	0.09	– 0.03–0.37
IB-XR	0.79	0.000	0.64–0.93	0.30	0.001	0.13–0.47
FOB-XR	0.83	0.000	0.71–0.96	0.57	0.000	0.39–0.74

Discussion

The present study showed that both FOB-XR and IB-XR are good predictors of the end-of-growth results, thus confirming that for good results, we need corrective braces and good brace management, with consistent brace wear, gradual weaning, and scoliosis-specific exercises. FOB-XR performed better than IB-XR. FOB-XR reflects the real correction and gives a specific target for clinicians, patients and parents to predict end results. We decided to test both the Cobb variation across radiographs taken during treatment and the correction rate to enhance the presented results' generalisability.

Brace treatment is recommended to halt progression of the curve and ensure a better quality of life in adulthood [1]. Regarding the brace effect, there is a long tradition of referencing the in-brace correction. Many authors have claimed the need for 30–50% curve correction to define brace effectiveness or to ensure a better probability of positive results. Other authors have specified higher rates, at least for severe curves. Whatever the case, a good correlation between the in-brace correction and the final results has been demonstrated [9] and was confirmed by the current findings. Katz found that 25% of in-brace correction was associated with a 73% success rate [10],

with success being considered a curve progression below 6 Cobb degrees. Landauer stated that over 40% of correction was significantly related to a successful outcome [4]. Goodboy recommended 45% in-brace correction to achieve treatment success [12]. To our knowledge, this is the first study to test how much correction should be kept at the first test of brace removal to achieve successful results. To allow comparison with other published results, we decided to use different outcome measures. The ROC curves indicated that the best predictor of success was the 30% correction rate in the IB-XR and the 10% correction rate in the FOB-XR.

We should highlight the solid clinical relevance of the present results. They will help clinicians assess short- and long-term brace outcomes and guide clinical choices and outcome communication with patients and their families. They also offer interesting insights for future research in the field. According to the present results, we recommend including the FOB-XR in future prognostic models when exploring brace treatment expectations. Patients will benefit too since they will better understand how treatment works and how to interpret brace results during the therapeutic path.

From the start of treatment, patients, families and clinicians look forward to predicting the end-of-growth results. An early indication of a good chance of success is essential

for clinical decision-making. Most importantly, it helps to motivate patients by encouraging them to adhere to the prescribed regimen and protocol.

The low level of missing data is a strength of routinely collected medical records and is dependent on the regular data checking, data completion, and data updates made by all the clinicians operating at our institute. Some patients showed worsening of the curve at IB-RX; this was not related to the brace effect but was usually due to the time between radiographs. To minimise ionising radiation, the START-XR can be done within the 3 months before the first visit. Therefore, it is possible that some patients performed the IB-XR 4 months after the START-XR. Curve progression could have occurred before brace fitting. There is, on average, a 2 month waiting list in Italy for obtaining a brace from the Public Health System. When this happens, the patients and their brace are checked and corrected if needed. We considered this factor a normal life variation controlled with a time variable added into the model. The time variable was insignificant, and therefore, it was not included in the final model. Since we aimed to test the prognostic role of radiographs, we did not exclude patients with the worst results from the analysis.

The present results highlight the different roles played by two essential parts of brace treatment. The IB-XR is fundamental to checking brace efficacy. When assessing the correction obtained, we encourage considering all the factors potentially involved, including patients' characteristics [16] such as spine flexibility, vertebral rotation, and skeletal maturity [7, 24]. Technical features of brace construction and wearing could impact brace correction too [25, 26]. Furthermore, correct prescription, brace type, brace material, and dosage, which stem from the clinical choices made by the expert clinicians, are expected to play a role in the brace correction. IB-XR should be used to optimise the correction by adjusting the brace accordingly [27].

Conversely, the FOB-XR plays a different role, shown by the more robust association with the end-of-growth results: it should be used to predict end results, adjust clinical choices, and motivate patients to comply with the prescription.

Conclusion

The FOB-XR reflects the real correction achieved and achievable by the patient and gives physicians, patients, and parents a specific target to predict results at the end of treatment. The FOB-XR is an important factor for future predictive models investigating the factors that determine the end-of-growth results in adolescents with idiopathic scoliosis.

Funding This research did not receive any specific grant from funding agencies in the public, commercial, or not-for-profit sectors.

Declarations

Conflict of interest SN declares stock from ISICO. FDF, FN, GR, FZ and SD have nothing to declare.

Ethical approval The study was approved by the local ethics committee (approval number: 254_2016bis).

Open Access This article is licensed under a Creative Commons Attribution 4.0 International License, which permits use, sharing, adaptation, distribution and reproduction in any medium or format, as long as you give appropriate credit to the original author(s) and the source, provide a link to the Creative Commons licence, and indicate if changes were made. The images or other third party material in this article are included in the article's Creative Commons licence, unless indicated otherwise in a credit line to the material. If material is not included in the article's Creative Commons licence and your intended use is not permitted by statutory regulation or exceeds the permitted use, you will need to obtain permission directly from the copyright holder. To view a copy of this licence, visit <http://creativecommons.org/licenses/by/4.0/>.

References

1. Negrini S, Donzelli S, Aulisa AG et al (2018) 2016 SOSORT guidelines: orthopaedic and rehabilitation treatment of idiopathic scoliosis during growth. *Scoliosis Spinal Disord.* <https://doi.org/10.1186/s13013-017-0145-8>
2. Weinstein SL, Dolan LA, Wright JG, Dobbs MB (2013) Effects of bracing in adolescents with idiopathic scoliosis. *N Engl J Med* 369:1512–1521. <https://doi.org/10.1056/NEJMoa1307337>
3. Guy A, Labelle H, Barchi S et al (2021) Braces designed using CAD/CAM combined or not with finite element modeling lead to effective treatment and quality of life after 2 years: a randomized controlled trial. *Spine* 46:9–16. <https://doi.org/10.1097/BRS.0000000000003705>
4. Landauer F, Wimmer C, Behensky H (2003) Estimating the final outcome of brace treatment for idiopathic thoracic scoliosis at 6-month follow-up. *Pediatr Rehabil* 6:201–207. <https://doi.org/10.1080/13638490310001636817>
5. Aulisa AG, Guzzanti V, Perisano C et al (2012) Treatment of lumbar curves in scoliotic adolescent females with progressive action short brace: a case series based on the scoliosis research society committee criteria. *Spine* 37:E786–791. <https://doi.org/10.1097/BRS.0b013e31824b547d>
6. Atanasio S, Zaina F, Negrini S (2008) The Sforzesco brace and sport concept: a brace to replace cast in worst curves. *Disabil Rehabil Assist Technol* 3:154–160. <https://doi.org/10.1080/17483100801905843>
7. Dolan LA, Weinstein SL, Abel MF et al (2019) Bracing in adolescent idiopathic scoliosis trial (BrAIST): development and validation of a prognostic model in untreated adolescent idiopathic scoliosis using the simplified skeletal maturity system. *Spine Deform* 7:890–898.e4. <https://doi.org/10.1016/j.jspd.2019.01.011>
8. Lonstein JE, Carlson JM (1984) The prediction of curve progression in untreated idiopathic scoliosis during growth. *J Bone Joint Surg Am* 66:1061–1071
9. De Mauroy JC, Pourret S, Barral F (2016) Immediate in-brace correction with the new lyon brace (ARTbrace): results of 141 consecutive patients in accordance with SRS criteria for bracing

- studies. *Ann Phys Rehabil Med* 59:e32. <https://doi.org/10.1016/j.rehab.2016.07.075>
10. Katz DE, Durrani AA (2001) Factors that influence outcome in bracing large curves in patients with adolescent idiopathic scoliosis. *Spine* 26:2354–2361. <https://doi.org/10.1097/00007632-200111010-00012>
 11. Emans JB, Kaelin A, Bancel P et al (1986) The boston bracing system for idiopathic scoliosis. follow-up results in 295 patients. *Spine* 11:792–801. <https://doi.org/10.1097/00007632-198610000-00009>
 12. Goodbody CM, Sankar WN, Flynn JM (2017) Presentation of adolescent idiopathic scoliosis: the bigger the kid, the bigger the curve. *J Pediatr Orthop* 37:41–46. <https://doi.org/10.1097/BPO.0000000000000580>
 13. Rigo M, Negrini S, Weiss HR et al (2006) SOSORT consensus paper on brace action: TLSO biomechanics of correction (investigating the rationale for force vector selection). *Scoliosis* 1:11. <https://doi.org/10.1186/1748-7161-1-11>
 14. Lang C, Huang Z, Sui W et al (2019) Factors that influence in-brace correction in patients with adolescent idiopathic scoliosis. *World Neurosurg* 123:e597–e603. <https://doi.org/10.1016/j.wneu.2018.11.228>
 15. Zaina F, de Mauroy JC, Donzelli S, Negrini S (2015) SOSORT award winner 2015: a multicentre study comparing the sport and art braces effectiveness according to the SOSORT-SRS recommendations. *Scoliosis* 10:23. <https://doi.org/10.1186/s13013-015-0049-4>
 16. Weinstein SL, Ponseti IV (1983) Curve progression in idiopathic scoliosis. *J Bone Joint Surg Am* 65:447–455
 17. Smania N, Picelli A, Romano M, Negrini S (2008) Neurophysiological basis of rehabilitation of adolescent idiopathic scoliosis. *Disabil Rehabil* 30:763–771. <https://doi.org/10.1080/17483100801921311>
 18. Richards BS, Bernstein RM, D'Amato CR, Thompson GH (2005) Standardization of criteria for adolescent idiopathic scoliosis brace studies: SRS committee on bracing and nonoperative management. *Spine* 30:2068–2075. <https://doi.org/10.1097/01.brs.0000178819.90239.d0>
 19. Negrini S, Donzelli S, Lusini M et al (2014) The effectiveness of combined bracing and exercise in adolescent idiopathic scoliosis based on SRS and SOSORT criteria: a prospective study. *BMC Musculoskelet Disord* 15:263. <https://doi.org/10.1186/1471-2474-15-263>
 20. Romano M, Negrini A, Parzini S et al (2015) SEAS scientific exercises approach to scoliosis: a modern and effective evidence based approach to physiotherapeutic specific scoliosis exercises. *Scoliosis* 10:3. <https://doi.org/10.1186/s13013-014-0027-2>
 21. Negrini S, Donzelli S, Negrini A et al (2019) Specific exercises reduce the need for bracing in adolescents with idiopathic scoliosis: a practical clinical trial. *Ann Phys Rehabil Med* 62:69–76. <https://doi.org/10.1016/j.rehab.2018.07.010>
 22. Negrini S, Hresko TM, O'Brien JP et al (2015) Recommendations for research studies on treatment of idiopathic scoliosis: consensus 2014 between SOSORT and SRS non-operative management committee. *Scoliosis* 10:8. <https://doi.org/10.1186/s13013-014-0025-4>
 23. Guo J, Deng X, Ling Q et al (2017) Reliability analysis of Cobb measurement in degenerative lumbar scoliosis using endplate versus pedicle as bony landmarks. *Postgrad Med* 129:762–767. <https://doi.org/10.1080/00325481.2017.1343645>
 24. Noshchenko A, Hoffecker L, Lindley EM et al (2015) Predictors of spine deformity progression in adolescent idiopathic scoliosis: a systematic review with meta-analysis. *World J Orthop* 6:537–558. <https://doi.org/10.5312/wjo.v6.i7.537>
 25. Pasha S (2019) 3D spinal and rib cage predictors of brace effectiveness in adolescent idiopathic scoliosis. *BMC Musculoskelet Disord* 20:384. <https://doi.org/10.1186/s12891-019-2754-2>
 26. Aubin CE, Labelle H, Ruskowski A et al (1999) Variability of strap tension in brace treatment for adolescent idiopathic scoliosis. *Spine* 24:349–354. <https://doi.org/10.1097/00007632-199902150-00010>
 27. Dolan LA, Donzelli S, Zaina F et al (2020) Adolescent idiopathic scoliosis bracing success is influenced by time in brace: comparative effectiveness analysis of BrAIST and ISICO cohorts. *Spine* 45:1193–1199. <https://doi.org/10.1097/BRS.0000000000003506>

Publisher's Note Springer Nature remains neutral with regard to jurisdictional claims in published maps and institutional affiliations.