J Surg Orthop Adv, 2007; 16(2): 98

Lettera all'Editore sull'articolo:
Adolescent Idiopathic Scoliosis: Modern Management Guidelines

Negrini S[1], Rigo M[2]
[1]ISICO (Istituto Scientifico Italiano Colonna vertebrale), Milano
[2]Instituto Èlena Salvá, Barcellona, Spagna.

Journal of Surgical Orthopaedic Advances — LETTERS TO THE EDITOR

RE: Adolescent Idiopathic Scoliosis: Modern Management Guidelines, Shindle, M. K., Khanna, A. J., Bhatnagar, R., Sponseller, P. D., JSOA 15(1): 43–52, 2006

Dear Editor:

I would like to thank you very much for the wonderful review by Shindle et al. (1), "Adolescent idiopathic scoliosis: modern management guidelines," published in the Spring 2006 issue of your journal. But, for the same reason we appreciated it, we also need to point out a couple of weaknesses in the treatment section of the article that must be carefully considered. Even if, from an historical point of view, in the last 20 years exercise as a treatment option for this condition has received scarce attention and its value today is still regarded with criticism, it's no longer possible to ignore the potential therapeutic role of exercise for adolescent idiopathic scoliosis (AIS). Two systematic reviews (2, 3) have shown the existence of many concordant positive results in controlled trials, and this has driven the choice of the only existing evidence-based guidelines (4) to give an evidence strength of C to exercise as a therapeutic option for AIS. Incidentally, this evidence strength is the same as that given to bracing, which means not the same efficacy as therapy, but the same strength for scientific proofs in terms of possible biases, that is, concordant results in many controlled trials (CCTs). Because there are only CCTs, as stated by Shindle et al. (1), some controversy still exists on bracing, but this therapeutic option is not as ignored as exercise, presumably because of past orthopaedic tradition.

The second point is that the world of bracing is not limited to the United States. Tools such as the Chêneau, the Lyon, and other braces (5) should be at least mentioned in an international journal with a worldwide readership.

Conservative treatment of AIS is today under question by many (1), but we all know that we cannot avoid searching for the best therapeutic approaches, possibly with no knives, rods, hooks, or screws. For this reason, a new International Society on Scoliosis Orthopaedic and Rehabilitation Treatment (SOSORT) was founded (5–8), as well as a new scientific journal, *Scoliosis* (www.scoliosisjournal.com) (7). We hope that in the future the evidence in this currently neglected field [more than 50% continued reduction of papers from the inception of Medline to 2005 (9)] will increase, in whichever direction, so as to offer the best appropriate treatment to our future: our own children.

Stefano Negrini
ISICO (Italian Scientific Spine Institute), Milan
General Secretary, International Society on Scoliosis Orthopaedic and Rehabilitation Treatment (SOSORT), www.sosort.org
Manuel Rigo
Istituto Elena Salvà Barcelona
President, International Society on Scoliosis Orthopaedic and Rehabilitation Treatment (SOSORT), www.sosort.org

References

1. Shindle, M. K., Khanna, A. J., Bhatnagar, R., Sponseller, P. D. Adolescent idiopathic scoliosis: modern management guidelines. J. Surg. Orthop. Adv. 15(1):43–52, 2006.
2. Negrini, S., Antonini, G., Carabalona, R., Minozzi, S. Physical exercises as a treatment for adolescent idiopathic scoliosis. A systematic review. Pediatr. Rehabil. 6(3–4):227–235, 2003.
3. Lenssinck, M. L., Frijlink, A. C., Berger, M. Y., Bierman-Zeinstra, S. M., Verkerk, K., Verhagen, A. P. Effect of bracing and other conservative interventions in the treatment of idiopathic scoliosis in adolescents: a systematic review of clinical trials. Phys. Ther. 85(12):1329–1339, 2005.
4. Negrini, S., Aulisa, L., Ferraro, C., et al. Italian guidelines on rehabilitation treatment of adolescents with scoliosis or other spinal deformities. Eura. Medicophys. 41(2):183–201, 2005.
5. Brace action: where to push and why. SOSORT 2005 Consensus Paper — Topic 2 (http://www.isico.it).
6. Physical exercises in the treatment of idiopathic scoliosis. SOSORT 2005 Consensus Paper — Topic 1 (http://www.isico.it).
7. Weiss, H. R. Scoliosis: a journal dedicated to multidisciplinary research on prevention, control, and treatment of scoliosis and other spinal deformities. Scoliosis 1(1):1, 2006.
8. Why we treat adolescent idiopathic scoliosis? What we want to obtain and to avoid for our patients. SOSORT 2005 Consensus Paper — Topic 3 (http://www.isico.it).
9. Negrini, S., Carabalona, R. Social acceptability of treatments for adolescent idiopathic scoliosis: a cross-sectional study. Scoliosis 1:14, 2006.

In Reply

Dear Editor:

The authors appreciate the additional information and perspective provided by Drs. Negrini and Rigo, who are respected researchers in many topics related to the pediatric spine. Our patients are constantly searching for alternatives to bracing and surgery, and to the difficulties they pose. The support for valid alternatives is strong. The Society and the Journal may assist in bringing forward valid studies and new ideas. We look forward to scientifically sound evidence on these topics.

Paul D. Sponseller, MD
Michael K. Shindle, MD
A. Jay Khanna, MD
Rishi Bhatnagar
(Note: Dr. Bhatnagar, who was a medical student at the time of this study, was unable to be contacted.)

98 JOURNAL OF SURGICAL ORTHOPAEDIC ADVANCES

La Lettera

Egregio Caporedattore,
desideriamo ringraziarLa molto per la stupenda revisione a opera di Schindle e altri[1] "Adolescent idiopathic scoliosis: modern management guidelines", pubblicata nel numero primaverile della Sua rivista. Tuttavia, per lo stesso motivo per il quale l'abbiamo apprezzata, desideriamo anche evidenziare un paio di punti deboli che abbiamo rilevato nella sezione dell'articolo dedicata al trattamento e che vanno attentamente considerati. Sebbene, da un punto di vista storico, negli ultimi 20 anni tali punti abbiano ricevuto scarsa attenzione e oggi siano ancora considerati negativamente, non è più possibile ignorare il potenziale ruolo terapeutico degli esercizi per la scoliosi idiopatica dell'adolescenza (AIS): due revisioni sistematiche[2 3], hanno dimostrato l'esistenza di molti risultati positivi concordi nell'ambito di studi controllati e tali risultati hanno determinato la scelta da parte delle uniche linee guida esistenti basate sull'evidenza[4] di attribuire una forza di evidenza pari a C agli esercizi, in qualità di opzione terapeutica per l'AIS. Fra l'altro, la forza dell'evidenza è la stessa che è stata assegnata al corsetto e ciò significa non la stessa efficacia a livello terapeutico, ma la stessa forza per le prove scientifiche in termini di possibili errori sistematici, cioè risultati concordi in molti studi controllati (CCT). Vista l'esistenza di soli studi controllati (CCT), come affermato da Schindle e altri[1], esistono tuttora alcune controversie sul corsetto, ma questa opzione terapeutica non è altrettanto ignorata come gli esercizi, presumibilmente a causa della tradizione ortopedica degli ultimi 20 anni.
Il secondo punto è che il mondo dei corsetti non finisce con gli Stati Uniti d'America: strumenti come il corsetto Chêneau, Lionese e altri[5] andrebbero almeno menzionati in una rivista medica internazionale con lettori in tutto il mondo.
Il trattamento conservativo della scoliosi idiopatica dell'adolescenza oggi è oggetto di studio da parte di molti[1], ma tutti noi sappiamo che non possiamo evitare di ricercare i migliori approcci terapeutici, possibilmente senza bisturi, aste, uncini o viti. Per questo motivo, è nata una nuova società internazionale per lo studio del trattamento ortopedico e riabilitativo della scoliosi (International Society on Scoliosis Orthopaedic and Rehabilitation Treatment - SOSORT)[5-8], così come una nuova rivista scientifica, "Scoliosis" (www.scoliosisjournal.com)[7]. Speriamo che in futuro l'evidenza in questo campo oggi così trascurato (si rileva, infatti, una riduzione costante, superiore al 50%, nel numero degli articoli dalla nascita di Medline fino al 2005[9]), possa aumentare in qualsiasi direzione, così da poter offrire il miglior trattamento possibile al nostro futuro: i nostri stessi figli.
Con i migliori saluti

Adolescent Idiopathic Scoliosis: Modern Management Guidelines
J Surg Orthop Adv 2006; 15(1): 43-52

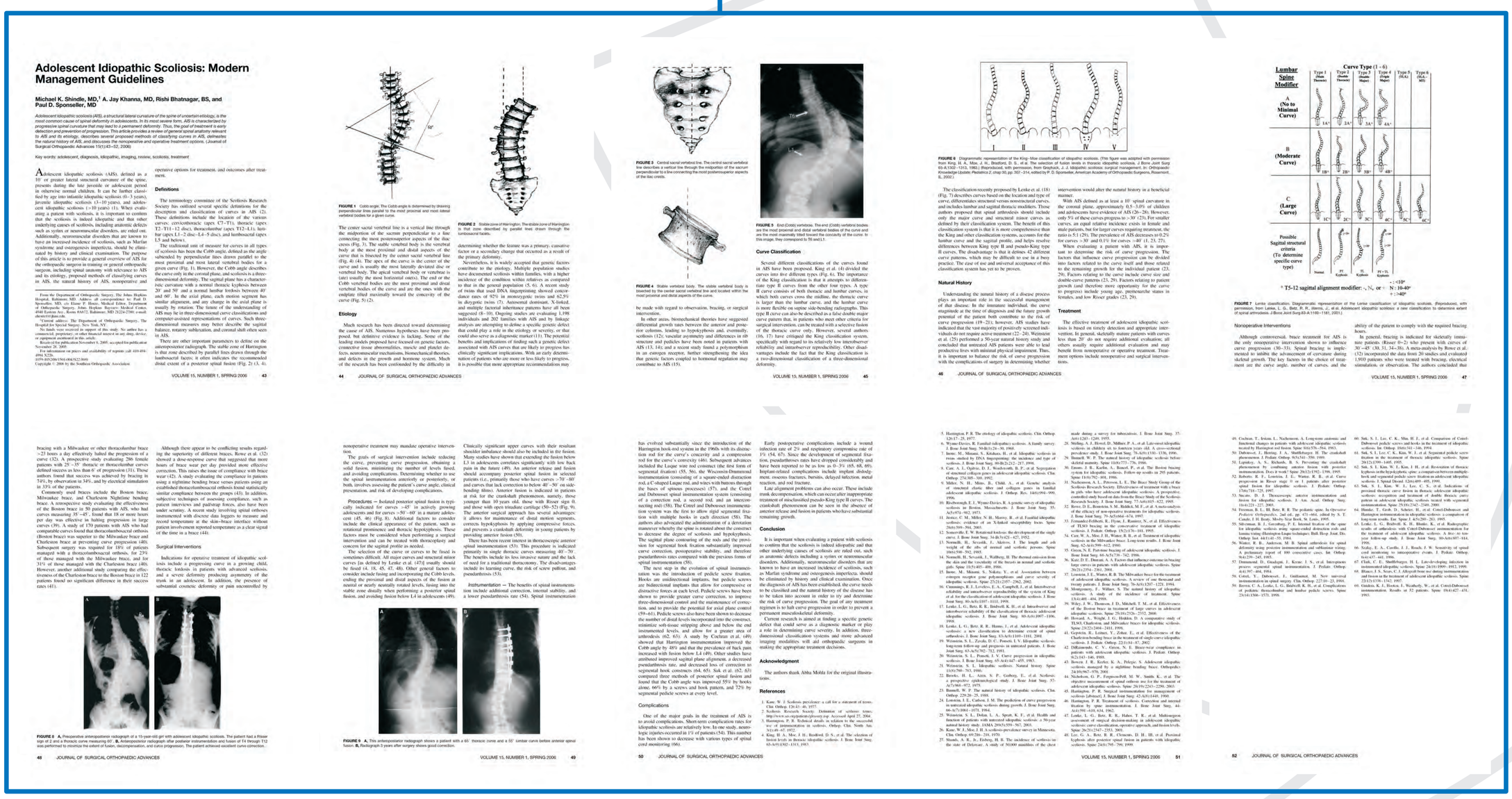

Adolescent Idiopathic Scoliosis: Modern Management Guidelines

Michael K. Shindle, MD,[1] A. Jay Khanna, MD, Rishi Bhatnagar, BS, and Paul D. Sponseller, MD

Adolescent idiopathic scoliosis (AIS), a structural lateral curvature of the spine of unknown etiology, is the most common cause of spinal deformity in adolescents. In its most severe form, AIS is characterized by progressive spinal curvature that may lead to a permanent deformity. Thus, the goal of treatment is early detection and prevention of progression. This article provides a review of general spinal anatomy relevant to AIS and its etiology, describes several proposed methods of classifying curves in AIS, delineates the natural history of AIS, and discusses the nonoperative and operative treatment options. (Journal of Surgical Orthopaedic Advances 15(1):43–52, 2006)

Key words: adolescent, diagnosis, idiopathic, imaging, review, scoliosis, treatment

Nonoperative Interventions

Although controversial, brace treatment for AIS is the only nonoperative intervention shown to influence curve progression (30–33). Spinal bracing is implemented to inhibit the advancement of curvature during skeletal growth. The key factors in the choice of treatment are the curve angle, number of curves, and the ability of the patient to comply with the required bracing hours.

In general, bracing is indicated for skeletally immature patients (Risser 0–2) who present with curves of 30°–45° (30, 31, 34–36). A meta-analysis by Rowe et al. (32) incorporated the data from 20 studies and evaluated 1,910 patients who were treated with bracing, electrical stimulation, or observation. The authors concluded that bracing with a Milwaukee or other thoracolumbar brace >23 hours a day effectively halted the progression of a curve (32). A prospective study evaluated 286 female patients with 25°–35° thoracic or thoracolumbar curves defined success in less than 6° progression (31). Those authors found that success was achieved by bracing in 74%, by observation in 34%, and by electrical stimulation in 33% of the patients.

Commonly used braces include the Boston brace, Milwaukee brace, and Charleston Nightime bending brace. A retrospective study evaluating the effectiveness of the Boston brace in 50 patients with AIS, who had curves measuring 35°–45°, found that 18 or more hours per day was effective in halting progression in large curves (39). A study of 170 patients with AIS who had comparable curves found that thoracolumbosacral orthosis (Boston brace) was superior to the Milwaukee brace and Charleston brace at preventing curve progression (40). Subsequent surgery was required for 18% of patients managed with a thoracolumbosacral orthosis, for 23% of those managed with the Milwaukee brace, and for 31% of those managed with the Charleston brace (40). However, another additional study comparing the effectiveness of the Charleston brace to the Boston brace in 122 patients found no significant difference in their success rates (41).

Although there appear to be conflicting results regarding the superiority of different braces, Rowe et al. (32) showed a dose-response curve that suggested that more hours of brace wear per day provided more effective correction. This raises the issue of compliance with brace wear (42). A study evaluating the compliance in patients using a nightime bending brace versus patients using an established thoracolumbosacral orthosis found statistically similar compliance between the groups (43). In addition, subjective techniques of assessing compliance, such as patient interviews and pad/strap forces, also have been under scrutiny. A recent study involving spinal orthoses instrumented with discrete data loggers to measure and record temperature at the skin–brace interface without patient involvement reported temperature as a clear signal of the time in a brace (44).

Surgical Interventions

Indications for operative treatment of idiopathic scoliosis include a progressing curve in a growing child, thoracic lordosis in patients with advanced scoliosis, and a severe deformity producing asymmetry of the trunk in an adolescent. In addition, the presence of substantial cosmetic deformity or pain uncontrolled by nonoperative treatment may mandate operative intervention.

The goals of surgical intervention include reducing the curve, preventing curve progression, obtaining a solid fusion, minimizing the number of levels fused, and avoiding complications. Determining whether to use the spinal instrumentation anteriorly or posteriorly, or both, involves assessing the patient's curve angle, clinical presentation, and risk of developing complications.

Procedures — Isolated posterior spinal fusion is typically indicated for curves <45° in actively growing adolescents and for curves >50°–60° in a mature adolescent (45, 46) (Fig. 8). Additional factors to consider include the clinical appearance of the patient, such as rotational prominence and thoracic hypokyphosis. These factors must be considered when performing a surgical intervention and can be treated with thoracoplasty and concern for the sagittal profile as needed.

The selection of the curve or curves to be fused is sometimes difficult. All major curves and structural minor curves [as defined by Lenke et al. (47)] usually should be fused (4, 18, 45, 47, 48). Other general factors to consider include fusing and incorporating the Cobb levels, ending the proximal and distal aspects of the fusion at neutrally neutrally rotated levels, fusing into the stable zone distally when performing a posterior spinal fusion, and avoiding fusion below L4 in adolescents (49).

Clinically significant upper curves with their resultant shoulder imbalance should also be included in the fusion. Many studies have shown that extending the fusion below L3 in adolescents correlates significantly with low back pain in the future (49). An anterior release and fusion should accompany posterior spinal fusion in selected patients (i.e., primarily those have curves >70°–80° and curves that lack correction to below 40°–50° on side-bending films). Anterior fusion is indicated in patients at risk for the crankshaft phenomenon, namely, those younger than 10 years old, those with Risser sign 0, and those with open triradiate cartilage (50–52) (Fig. 9). The anterior surgical approach has several advantages: it allows for maintenance of distal motion segments, corrects hypokyphosis by applying compressive forces, and prevents a crankshaft deformity in young patients by providing anterior fusion (50).

There has been recent interest in thoracoscopic anterior instrumentation for scoliosis. This procedure is indicated primarily in single thoracic curves measuring 40°–70°. The benefits include its less invasive nature and the lack of need for a traditional thoracotomy. The disadvantages include its learning curve, the risk of screw pullout, and pseudarthrosis (53).

Instrumentation — The benefits of spinal instrumentation include immediate correction, internal stability, and a lower pseudarthrosis rate (54). Spinal instrumentation has evolved substantially since the introduction of the Harrington hook-rod system in the 1960s with its distraction rod for the curve's concavity and a compression rod for the curve's convexity (46). Subsequent advances included the Luque wire rod construct (the first form of segmental fixation) (55, 56), the Wisconsin-Drummond instrumentation (consisting of a square-ended distraction rod, a C-shaped Luque rod, and wires with buttons through the bases of spinous processes) (57), and the Cotrel and Dubousset spinal instrumentation system (consisting of a correction rod, a second rod, and an interconnecting rod) (58). The Cotrel and Dubousset instrumentation system was the first to allow rigid segmental fixation with multiple hooks and rods (58). Contemporary authors also advocated the administration of a derotation maneuver whereby the spine is rotated about the construct to decrease the degree of scoliosis and hypokyphosis. The sagittal plane contouring of the rods and the provision for segmental fixation substantially improved curve correction, postoperative stability, and therefore pseudarthrosis rates compared with the previous forms of spinal instrumentation (58).

The next step in the evolution of spinal instrumentation was the introduction of pedicle screw fixation. Hooks are unidirectional implants, but pedicle screws are bidirectional implants that allow for compressive or distractive forces at each level. Pedicle screws have been shown to provide greater curve correction, to improve three-dimensional control and the maintenance of correction, and to provide the potential for axial plane control (59–61). Pedicle screws also have been shown to decrease the number of distal levels incorporated into the construct, minimize soft-tissue stripping above and below the end instrumented levels, and allow for a greater area of arthrodesis (62, 63). A study by Cochran et al. (49) showed that Harrington instrumentation improved the Cobb angle by 48% and that the prevalence of hook pain increased with fusion below L4 (49). Other studies have attributed improved sagittal plane alignment, a decreased pseudarthrosis rate, and decreased loss of correction to segmental hook constructs (64, 65). Suk et al. (62, 63) compared three methods of posterior spinal fusion and found that the Cobb angle was improved 55% by hooks alone, 66% by a screws and hook pattern, and 72% by segmental pedicle screws at every level.

Complications

One of the major goals in the treatment of AIS is to avoid complications. Short-term complication rates for idiopathic scoliosis are relatively low. In one study, neurologic injuries occurred in 1% of patients (54). This number has been shown to decrease with various types of spinal cord monitoring (66).

Early postoperative complications include a wound infection rate of 2% and respiratory compromise rate of 1% (54, 67). Since the development of segmental fixation, pseudarthroses rates have dropped considerably and have been reported to be as low as 0–3% (65, 68, 69). Implant-related complications include implant dislodgment, osseous fractures, breakage, delayed infection, metal reaction, and rod fracture.

Late alignment problems can also occur. These include trunk decompensation, which can occur after inappropriate treatment of misclassified pseudo-King type II curves. The crankshaft phenomenon can be seen in the absence of anterior release and fusion in patients who have substantial remaining growth.

Conclusion

It is important when evaluating a patient with scoliosis to confirm that the scoliosis is indeed idiopathic and that other underlying causes of scoliosis are ruled out, such as anatomic defects including a syrinx or neuromuscular disorders. Additionally, neuromuscular disorders that are known to have an increased incidence of scoliosis, such as Marfan syndrome and osteogenesis imperfecta, should be eliminated by history and clinical examination. Once the diagnosis of AIS has been established, the curve needs to be classified and the natural history of the disease has to be taken into account in order to try and determine the risk of curve progression. The goal of any treatment regimen is to halt curve progression in order to prevent a permanent musculoskeletal deformity.

Current research is aimed at finding a specific genetic test that could serve as a diagnostic marker or play a role in determining curve severity. In addition, three-dimensional classification systems and more advanced imaging modalities will aid orthopaedic surgeons in making the appropriate treatment decisions.

Acknowledgment

The authors thank Abha Mohla for the original illustrations.

References

1. Kane, W. J. Scoliosis prevalence: a call for a statement of terms. Clin. Orthop. 126:43–46, 1977.
2. Scoliosis Research Society. Definition of scoliosis terms. http://www.srs.org/patients/glossary.jsp. Accessed April 27, 2004.
3. Harrington, P. R. Technical details in relation to the successful use of instrumentation in scoliosis. Orthop. Clin. North Am. 3(1):49–67, 1972.
4. King, H. A., Moe, J. H., Bradford, D. S., et al. The selection of fusion levels in thoracic idiopathic scoliosis. J. Bone Joint Surg. 65-A(8):1302–1313, 1983.
5. Harrington, P. R. The etiology of idiopathic scoliosis. Clin. Orthop. 126:17–25, 1977.
6. Wynne-Davies, R. Familial (idiopathic) scoliosis. A family survey. J. Bone Joint Surg. 59-B(1):24–30, 1968.
7. Inoue, M., Minami, S., Kitahara, H., et al. Idiopathic scoliosis in twins studied by DNA fingerprinting: the incidence and type of scoliosis. J. Bone Joint Surg. 80-B(2):212–217, 1998.
8. Carr, A. J., Ogilvie, D. J., Worthington, B. P., et al. Segregation of structural collagen genes in adolescent idiopathic scoliosis. Clin. Orthop. 274:300–310, 1992.
9. Miller, N. H., Minn, B., Child, A., et al. Genetic analysis of structural collagen genes in a family with and without adolescent idiopathic scoliosis. J. Orthop. Res. 14(6):994–999, 1996.
10. Riseborough, E. J., Wynne-Davies, R. A genetic survey of idiopathic scoliosis in Boston, Massachusetts. J. Bone Joint Surg. 55-A(5):974–982, 1973.
11. Justice, C. M., Miller, N. H., Marosy, B., et al. Familial idiopathic scoliosis: evidence of an X-linked susceptibility locus. Spine 28(8):789–794, 2003.
12. Somerville, E. W. Rotational lordosis: the development of the single curve. J. Bone Joint Surg. 36-B(1):421–427, 1952.
13. Normell, H., Sevastik, J., Aaroen, J. The length and arch weight of the ribs of normal and scoliotic persons. Spine 10(6):590–592, 1985.
14. Normell, H., Sevastik, J., Wallberg, H. The thermal emission from the skin and the vascularity of the breasts in normal and scoliotic girls. Spine 11(5):402–406, 1986.
15. Inoue, M., Minami, S., Nakata, Y., et al. Association between estrogen receptor gene polymorphisms and curve severity of idiopathic scoliosis. Spine 27(21):2357–2362, 2002.
16. Cummings, R. J., Loveless, E., Ca., Campbell, J., et al. Interobserver reliability and intraobserver reproducibility of the system of King et al. for the classification of adolescent idiopathic scoliosis. J. Bone Joint Surg. 80-A(8):1307–1318, 1998.
17. Lenke, L. G., Betz, R. R., Bridwell, K. H., et al. Intraobserver and interobserver reliability of the classification of thoracic adolescent idiopathic scoliosis. J. Bone Joint Surg. 80-A(8):1097–1106, 1998.
18. Lenke, L. G., Betz, R. R., Harms, J., et al. Adolescent idiopathic scoliosis: a new classification to determine extent of spinal arthrodesis. J. Bone Joint Surg. 83-A(8):1169–1181, 2001.
19. Weinstein, S. L., Zavala, D. C., Ponseti, I. V. Idiopathic scoliosis: long-term follow-up and prognosis in untreated patients. J. Bone Joint Surg. 63-A(5):702–712, 1981.
20. Weinstein, S. L., Ponseti, I. V. Curve progression in idiopathic scoliosis. J. Bone Joint Surg. 65-A(4):447–455, 1983.
21. Weinstein, S. L. Idiopathic scoliosis. Natural history. Spine 11(9):780–783, 1986.
22. Brooks, H. L., Azen, S. P., Gerberg, E., et al. Scoliosis: a prospective epidemiological study. J. Bone Joint Surg. 57-A(7):968–972, 1975.
23. Bunnell, W. P. The natural history of idiopathic scoliosis. Clin. Orthop. 229:20–28, 1988.
24. Lowstein, J. L., Carlson, J. M. The prediction of curve progression in untreated idiopathic scoliosis during growth. J. Bone Joint Surg. 66-A(7):1061–1071, 1984.
25. Weinstein, S. L., Dolan, L. A., Spratt, K. F., et al. Health and function of patients with untreated idiopathic scoliosis: a 50-year natural history study. JAMA 289(5):559–567, 2003.
26. Kane, W. J. Mass J. H. A scoliosis-prevalence survey in Minnesota. Clin. Orthop. 69:288–238, 1970.
27. Shands, A. R., Jr., Eisberg, H. B. The incidence of scoliosis in the state of Delaware. A study of 50,000 stadiums of the chest made during a survey for tuberculosis. J. Bone Joint Surg. 37-A(6):1243–1249, 1955.
28. Stirling, A. J., Howel, D., Millner, P. A., et al. Late-onset idiopathic scoliosis in children yet to fourteen years old. A cross-sectional prevalence study. J. Bone Joint Surg. 78-A(9):1330–1336, 1996.
29. Bunnell, W. P. The natural history of idiopathic scoliosis before skeletal maturity. Spine 11(6):773–776, 1986.
30. Emans, J. B., Kaufm, A., Hassel, P., et al. The Boston bracing system for idiopathic scoliosis. Follow-up results in 295 patients. Spine 11(6):792–801, 1986.
31. Nachemson, A. L., Peterson, L. E. The Brace Study Group of the Scoliosis Research Society. Effectiveness of treatment with a brace in girls who have adolescent idiopathic scoliosis. A prospective, controlled study based on data from the Brace Study of the Scoliosis Research Society. J. Bone Joint Surg. 77-A(6):815–822, 1995.
32. Rowe, D. E., Bernstein, S. M., Riddick, M. F., et al. A meta-analysis of the efficacy of non-operative treatments for idiopathic scoliosis. J. Bone Joint Surg. 79-A(4):624–635, 1997.
33. Fernandez-Feibrich, K., Flynn, J., Ramirez, N., et al. Effectiveness of TLSO bracing in the conservative treatment of idiopathic scoliosis. J. Pediatr. Orthop. 15(2):176–181, 1995.
34. Carr, W. A., Moe, J. H., Winter, R. B., et al. Treatment of idiopathic scoliosis in the Milwaukee brace. Long-term results. J. Bone Joint Surg. 62-A(4):599–612, 1980.
35. Green, N. E. Part-time bracing of adolescent idiopathic scoliosis. J. Bone Joint Surg. 68-A(5):738–742, 1986.
36. Katz, D. E., Durrant, A. A. Factors that influence outcome in bracing large curves in patients with adolescent idiopathic scoliosis. Spine 26(21):2354–2361, 2001.
37. Lonstein, J. E., Winter, R. B. The Milwaukee brace for the treatment of adolescent idiopathic scoliosis. A review of one thousand and twenty patients. J. Bone Joint Surg. 76-A(8):1207–1221, 1994.
38. Montgomery, F., Willner, S. The natural history of idiopathic scoliosis. A study of the incidence of treatment. Spine 13(4):401–404, 1988.
39. Wiley, J. W., Thomson, J. D., Mitchell, T. M., et al. Effectiveness of the Boston brace in treatment of large curves in adolescent idiopathic scoliosis. Spine 25(18):2326–2332, 2000.
40. Howard, A., Wright, J. G., Hedden, D. A comparative study of TLSO, Charleston, and Milwaukee braces for idiopathic scoliosis. Spine 23(22):2484–2491, 1998.
41. Gepstein, R., Lerner, Y., Zohar, E., et al. Effectiveness of the Charleston bending brace in the treatment of single-curve idiopathic scoliosis. J. Pediatr. Orthop. 22(1):84–87, 2002.
42. DiRaimondo, C. V., Green, N. E. Brace-wear compliance in patients with adolescent idiopathic scoliosis. J. Pediatr. Orthop. 8(2):143–146, 1988.
43. Bowen, J. R., Keeler, K. A., Pelegie, S. Adolescent idiopathic scoliosis managed by a nightime bending brace. Orthopedics 24:10(967–970, 2001.
44. Nicholson, G. P., Ferguson-Pell, M. W., Smith, K., et al. The objective measurement of spinal orthosis use for the treatment of adolescent idiopathic scoliosis. Spine 29(19):2243–2250, 2003.
45. Harrington, P. R. Surgical instrumentation for management of scoliosis [abstract]. J. Bone Joint Surg. 42-A(6):1448, 1960.
46. Harrington, P. R. Treatment of scoliosis. Correction and internal fixation by spine instrumentation. J. Bone Joint Surg. 44-A(4):591–610, 634, 1962.
47. Lenke, L. G., Betz, R. R., Haher, T. R., et al. Multisegmental assessment of surgical decision-making in adolescent idiopathic scoliosis: curve classification, operative approach, and fusion levels. Spine 26(21):2347–2353, 2001.
48. Lee, G. A., Betz, R. R., Clements, D. H., III, et al. Proximal kyphosis after posterior spinal fusion in patients with idiopathic scoliosis. Spine 24(8):795–799, 1999.
49. Cochran, T., Irstam, L., Nachemson, A. Long-term anatomic and functional changes in patients with adolescent idiopathic scoliosis treated by Harrington rod fusion. Spine 8(6):576–584, 1983.
50. Dubousset, J., Herring, J. A., Shufflebarger, H. The crankshaft phenomenon. J. Pediatr Orthop 9(5):541–550, 1989.
51. Lapinsky, A. S., Richards, B. S. Preventing the crankshaft phenomenon by combining anterior fusion with posterior instrumentation. Does it work? Spine 29(12):1392–1398, 1995.
52. Roberto, R. F., Lonstein, J. E., Winter, R. B., et al. Curve progression in Risser stage 0 or 1 patients after posterior spinal fusion for idiopathic scoliosis. J. Pediatr. Orthop. 17(6):720–725, 1997.
53. Sucato, D. J. Thoracoscopic anterior instrumentation and fusion for idiopathic scoliosis. J. Am. Acad. Orthop. Surg. 11(4):221–227, 2003.
54. Freeman, B. L., III, Betz, R. R. The pediatric spine. In *Operative Pediatric Orthopaedics*, 2nd ed., pp. 471–664, edited by S. T. Canale, J. H. Beaty. Mosby-Year Book, St. Louis, 1995.
55. Silverman, B. J., Greenberg, P. E. Internal fixation of the spine for idiopathic scoliosis using square-ended distraction rods and lamina wiring (Harrington-Luque technique). Bull. Hosp. Joint. Dis. Orthop. Inst. 44(1):41–55, 1984.
56. Winter, R. B., Anderson, M. B. Spinal orthoskeleton for spinal deformity using posterior instrumentation and sublaminar wiring. A preliminary report of 100 consecutive cases. Int. Orthop. 9(4):239–245, 1985.
57. Drummond, D., Guadagni, J., Keene, J. S., et al. Interspinous process segmental spinal instrumentation. J. Pediatr. Orthop. 4(4):397–404, 1984.
58. Cotrel, Y., Dubousset, J., Guillaumat, M. New universal instrumentation in spinal surgery. Clin. Orthop. 227:10–23, 1988.
59. Beaven, C. A., Lenke, L. G., Bridwell, K. H., et al. Complications of pediatric thoracolumbar and lumbar pedicle screws. Spine 28(14):1566–1573, 1998.
60. Suk, S. I., Lee, C. K., Min, H. J., et al. Comparison of Cotrel-Dubousset pedicle screws and hooks in the treatment of idiopathic scoliosis. Int. Orthop. 18(6):341–346, 1994.
61. Suk, S. I., Lee, C. K., Kim, W. J., et al. Segmental pedicle screw fixation in the treatment of thoracic idiopathic scoliosis. Spine 20(12):1399–1405, 1995.
62. Suk, S. I., Kim, W. J., Kim, J. H., et al. Restoration of thoracic kyphosis in the hypokyphotic spine: a comparison between multihook and segmental pedicle screw fixation in adolescent idiopathic scoliosis. J. Spinal Disord. 12(6):491–495, 1999.
63. Suk, S. I., Lee, C. K., Kim, W. J., et al. Indications of proximal thoracic curve fusion in thoracic adolescent idiopathic scoliosis: recognition and treatment of double thoracic curve pattern in adolescent idiopathic scoliosis treated with segmental instrumentation. Spine 25(18):2342–2349, 2000.
64. Hinuke, T., Grob, D., Scheier, H., et al. Cotrel-Dubousset and Harrington instrumentation in idiopathic scoliosis: a comparison of long-term results. Eur. Spine J. 4(5):281–283, 1995.
65. Lenke, L. G., Bridwell, K. H., Blanke, K., et al. Radiographic results of arthrodesis with Cotrel-Dubousset instrumentation for the treatment of adolescent idiopathic scoliosis. A five- to ten-year follow-up study. J. Bone Joint Surg. 80-A(8):1087–1014, 1998.
66. Scaglione, M., Carrillo, J. J., Roach, J. W. Sensitivity of spinal cord monitoring to intraoperative events. J. Pediatr. Orthop. 16(4):437–441, 1996.
67. Clark, C. E., Shufflebarger, H. L. Late-developing infection in instrumented idiopathic scoliosis. Spine 24(18):1909–1912, 1999.
68. Blanco, J. S., Sears, C. J. Allograft bone use during instrumentation and fusion in the treatment of adolescent idiopathic scoliosis. Spine 23(12):1338–1342, 1997.
69. Gaskins, K. A., Hoskin, J. Weatherly, W., et al. Cotrel-Dubousset instrumentation. Results in 52 patients. Spine 18(4):427–431, 1993.